



Neutral Citation Number: [2019] EWHC 938 (QB)

Case No: CF058/2018CA

**IN THE HIGH COURT OF JUSTICE**  
**HIGH COURT APPEAL CENTRE CARDIFF**  
**On appeal from the Cardiff Civil Justice Centre**  
**Order of HHJ Petts dated 31 August 2018**  
**County Court case number: B90CF028**

Cardiff Civil Justice Centre,  
2 Park Street,  
Cardiff CF10 1ET

Date: 15/04/2019

**Before :**

**MR JUSTICE BIRSS**

-----  
**Between :**

**David Price**  
**- and -**  
**Cwm Taf University Health Board**

**Appellant**

**Respondent**

-----  
**Theo Huckle QC and David Haines (instructed by Thompsons) for the Appellant**  
**Charles Bagot QC and Vanessa McKinlay (instructed by NHS Wales Shared Service**  
**partnership) for the Respondent**

Hearing dates: 6th, 7th March 2019  
-----

**Judgment Approved by the court**  
**for handing down**  
**(subject to editorial corrections)**

<p><b>If this Judgment has been emailed to you it is to be treated as ‘read-only’.</b> <b>You should send any suggested amendments as a separate Word document.</b></p>
---

**Mr Justice Birss :**

1. This is an appeal from the judgment of HHJ Petts given on 31<sup>st</sup> August 2018 after a trial 26<sup>th</sup>-28<sup>th</sup> February and 21<sup>st</sup> May 2018. The last day of the four day trial had to be delayed because the court closed due to bad weather. The judge heard Mr Price's medical negligence claim arising out of three operations on his right knee carried out on 15<sup>th</sup> February 2011, 26<sup>th</sup> November 2011 and 30<sup>th</sup> April 2012 at the Prince Charles Hospital in Merthyr Tydfil. The conducting orthopaedic surgeon was Mr Sharma. The first two operations were arthroscopy procedures and the third was a partial knee replacement using an Oxford Unicompartmental prosthesis. After the third operation, Mr Price had ongoing and persistent pain and Mr Sharma referred him to another surgeon at Llandough Hospital. Mr Price had a full knee replacement on 20<sup>th</sup> May 2013.
2. In a clearly structured judgment, following an introduction the judge accurately summarised the circumstances from paragraphs 11 to 38, addressed the first operation from paragraphs 39-48, the second operation from paragraphs 49-69 and the third operation from paragraph 70-87. The judge concluded by explaining that he had great sympathy for Mr Price's situation and what he had been through, nevertheless he held that the claim should be dismissed.
3. In relation to the first arthroscopy operation the issue was about consent. When the arthroscopy was undertaken a microfracture procedure was also performed. The judge found that the proper consent of Mr Price to that further aspect had not been obtained. However this part of the claim failed because the judge also held that if the consent process had been gone through properly then Mr Price would have had the microfracture procedure in any event. I refused permission to appeal on this issue on paper and the point was not pursued further. There is not now any appeal relating to the first operation.
4. For the second arthroscopy the issue was the decision to proceed with the operation. Mr Price's case was that an arthroscopy was not indicated for a patient in his position, was contrary to the NICE Guidelines and was a pointless operation to perform on him. An aspect of this point was another issue about consent, in that the consent form did not record any benefits for the operation and did not inform Mr Price that it was not indicated by the NICE Guidelines. Mr Price sought permission to appeal on these findings. I gave permission on paper. The matter will be addressed below.
5. The third operation was a partial knee replacement. The issue before the judge resolved down to a question of fact. Mr Price's case at trial and on appeal is that the femoral component of the prosthesis was installed in such a way that it was misaligned. The manufacturer's specification permits the component to be aligned +/- 10° to the relevant reference axis. Mr Price's case was that the component was in fact aligned at about 17° or more. That was based on a composite X-ray image dated 15<sup>th</sup> October 2012 which was referred to at trial as the Long Leg image. The defendant's case was that the femoral component was not misaligned. The judge decided that the Long Leg Image was not one on which reliance could be placed. He also held that the relevant angle was no more than 6°. Accordingly the femoral component had not been negligently installed and the claim for the third operation failed. As a result the overall claim was rejected. On appeal Mr Price contends that the judge erred in various ways in his decision about the angle. I gave permission to appeal on that point.

6. Although other points were taken in the grounds of appeal, by the conclusion of Mr Price's counsel's speech the only issues are the two grounds I have mentioned. It is common ground that if the appeal on either or both of the second or third operations succeeds then there would need to be a further hearing to decide quantum and causation if the matter cannot be agreed. In the context of this case the sum arising from the second operation would be relatively modest but that is no reason not to examine the issue properly.

### *The appeal*

7. Both grounds of appeal relate to findings of fact by the trial judge. In such cases appellants often approach the matter by seeking to persuade the appellate court what the facts are and then inviting a conclusion that the appeal should be allowed because the judge came to a different conclusion and therefore erred. That is not the right approach, particularly when the first step is necessarily based on edited highlights from the evidence below. The most important principle which I must keep in mind at all times is to remember that I am not the trial judge. The question is not - what do I think the facts are? The question is - has the trial judge erred in finding the facts as he or she has found them to be?
8. In ***Wheeldon v Millenium Insurance Co. Ltd*** [2018] EWCA 2403 Coulson LJ considered the principles applicable to appeals on a finding of fact. He set out a number of passages on the point: paragraph 114 from the judgement of Lewison LJ in ***Fage v Chobani*** [2014] EWCA Civ 5 which includes the well known observation about a judge's reasons; paragraph 67 from Lord Reid's speech in ***Henderson v Foxworth*** [2014] UKSC 41; and paragraphs 39 and 40 of Longmore LJ in ***Grizzly Business Ltd v Stena Drilling Ltd*** [2017] EWCA Civ 94. After that Coulson LJ summarised the position as follows:

“10. In short, to be overturned on appeal, a finding of fact must be one that no reasonable judge could have reached. In practice, that will usually occur only where there was no evidence at all to support the finding that was made, or the judge plainly misunderstood the evidence in order to arrive at the disputed finding.”

9. I turn to consider the two grounds of appeal.

### *Second operation*

10. The circumstances in which the second arthroscopy was performed were these. Mr Price's first arthroscopy had been performed in February 2011. At that time he was working as aircraft engineer at GE Aircraft Engines. By 2<sup>nd</sup> May Mr Price was still off work due to a problem with his wrist, which was due for surgery on 26<sup>th</sup> May 2011. In September 2011 one of Mr Sharma's registrars saw him. The relevant passages from the clinic letter are quoted in the judgment at paragraph 29. Mr Price was extremely upset as things had got much worse after his first operation. The letter records that the registrar, Mr Sharma and Mr Price had discussed the possibility of knee replacement and also lifestyle modification and changing the nature of his job. Mr Price did not wish to change his job. The second arthroscopy was performed some weeks later.

11. The judge found that Mr Price was not a typical patient with osteoarthritis in the knee given his comparatively young age (he was 52 at the time of the first arthroscopy) and found that Mr Sharma was reasonably motivated by a desire to postpone carrying out knee replacement surgery given the implications this might have for Mr Price's employment.
12. There is no suggestion that the second arthroscopy itself was performed negligently. The arguments presented on Mr Price's behalf on appeal are that the operation was not indicated at all and that the consent process was not done correctly, bearing in mind the omissions from the consent form. In effect the appeal puts together the question of whether carrying out the operation was negligent with the issue of consent.
13. In relation to consent itself it was also argued that the judge's reasons were insufficient. When the application for permission to appeal came before me on paper it was not clear whether the guidance at paragraph 25 of *English v Emery Reimbold* [2002] EWCA Civ 605 had been followed, albeit that an application for permission to appeal had been made to the trial judge. I gave permission on paper but also invited the appellant to consider inviting the judge to give further reasons. The appellant's solicitors wrote to the court but by the time of the hearing of this appeal they had received no reply. However shortly after the hearing the parties received a supplemental judgment from the judge dealing with the issue. I invited and received written submissions from both parties on any points arising. The appellant's case was that the supplemental judgment did not alter his case on appeal. There is no need for a further oral hearing. I have taken the written submissions into account in deciding this appeal.
14. The appellant's case on the second operation is as follows:
  - i) In the main judgment the judge failed to address consent properly and made no finding. There was no evidence Mr Price consented. No risks/benefits were ever documented or advised to him. The consenting process and the signed consent form were wholly inadequate.
  - ii) The decision to undertake the operation was flawed because the procedure was not indicated and was contrary to the NICE Guidelines. The judge was wrong to suggest in paragraph 63 of the judgment that failing to follow NICE Guidelines was not prima facie evidence of negligence. This is wrong as a general proposition and was wrong in this case.
  - iii) Mr Price's knee was degenerate and already required knee replacement surgery, which was inevitable in due course. Postponing a replacement in favour of a different procedure under general anaesthetic could only be justified if there were real gains to be achieved and could only be properly consented to if the patient understood and agreed to seek to achieve them. Viewed objectively there were no such gains and none are suggested in the consent form. The judge excused this as an "error" but could only identify a single reason actually offered namely to put right the frayed cartilage from the first operation. Mr Price was not given the information necessary to make a reasoned choice and *Webb v Barclays Bank* [2001] EWCA Civ 1141 applies.
  - iv) In finding as the judge did in paragraph 66 that while the chances were low there was a chance of delaying knee replacement surgery further, which was clearly

in Mr Price's best interests, the judge adopted a paternalistic approach which had been discredited in *Chester v Afshar* [2004] UKHL 41 and *Montgomery v Lanarkshire Health Board* [2015] UKSC 1.

15. In the supplemental judgment at paragraph 99 (numbered consecutively from the main judgment) the judge made an express finding that the reasons for the second arthroscopy were properly explained to Mr Price. In paragraph 100 the judge went on to consider an alternative case and rejected that too. The appellant's case is:
  - i) While an appeal court may take a second judgment into account (*Roche v Chief Constable of Greater Manchester* [2005] EWCA Civ 1545), nevertheless, *Michael Hyde v J D Williams* [2000] EWCA Civ 211, [2001] PNLR 233 is authority for the proposition that it is inappropriate to go back to the trial judge for clarification or amplification many months after the original judgment was delivered; and in *Aerospace Publishing v Thames Water Utilities* [2006] EWCA Civ 717 the court warned of the danger of *ex post facto* rationalisation by a judge later providing such amplification.
  - ii) The findings do not alter the case on appeal. The findings should be treated with caution for the reasons set out in (i). Also they are not understood since the respondent did not cross-examine Mr Price on the relevant basis. In any event they are unsupported.
16. To address the issues on the second operation I will separate the treatment decision from the issue of consent.

#### *The treatment decision*

17. In relation to the treatment decision the judge preferred the orthopaedic surgery expert evidence of Mr Weale, called by the respondents, to that of Mr Rickman, called by Mr Price. The judge was entitled to do so for the reason he gave, namely the unconvincing change in Mr Rickman's evidence and his rejection of the submission on Mr Price's behalf that Mr Weale was a "hired gun" (paragraph 68).
18. The judge's finding in paragraph 68 was that

"Overall, while Mr Sharma was not in the mainstream view in carrying out a further arthroscopy on the claimant bearing in mind the NICE Guidelines, he was within a reasonable body of orthopaedic surgeons who would reasonably have carried out such a procedure."
19. That finding was firmly supported by Mr Weale's evidence and so the judge was entitled to reach that conclusion. This would be a sufficient basis to dismiss that aspect of this ground of appeal, but before deciding what to do I will focus on the NICE Guidelines.
20. As the judge recognised (paragraph 49), the NICE Guidelines state that arthroscopy should not be offered as part of treatment for osteoarthritis unless the person has knee osteoarthritis with a clear history of mechanical locking. There had been a point at trial about mechanical locking but the judge held that Mr Sharma was wrong to equate Mr

Price's catching within the knee as relevant mechanical locking. Therefore, the submission on Mr Price's behalf is that in effect the arthroscopy was being used as a treatment for osteoarthritis but that is contrary to the NICE Guidelines.

21. However as the judge recognised in paragraph 63 the Guidelines also make clear that while they have been arrived at after careful consideration they do not override the individual responsibility of healthcare professionals to make decisions appropriate to the circumstances of the individual patient. After noting that they do not override the need for appropriate individual decisions the judge then made the statement which is challenged on appeal: "nor is failing to follow the guidelines *prima facie* evidence of negligence."
22. I decline to be drawn into what could be a far reaching debate about whether any departure from any aspect of the NICE Guidelines is or is not *prima facie* evidence of negligence. I agree with the judge that this departure from these guidelines is not *prima facie* evidence of negligence. Nevertheless what must be right is that a clinical decision which departs from the NICE Guidelines is likely to call for an explanation of some sort. The nature and degree of detail required will depend on all the circumstances. The only relevant question on this appeal is whether the particular decision in this case, which does depart from the guidelines, has been adequately explained and justified. The answer is that the departure has been justified, for the reasons already given. There is nothing in the NICE Guidelines point to support an appeal relating to the treatment decision itself. Accordingly insofar as it seeks to impugn the treatment decision relating to the second operation, this part of the appeal fails.

### *Consent*

23. I turn to consider the consent. The judge held (paragraph 66) that there were potential benefits to Mr Price from the operation and the state of the consent form was simply due to error and not indicative of a situation in which there were no benefits. The judge also held that the reason for the operation which is set out in a clinic letter was a potential benefit to Mr Price. That was to trim any frayed cartilage from the microfracture in the first operation.
24. The argument on Mr Price's behalf, based on an analogy with Webb, comes down to a submission that Mr Price ought to have been told that the operation was not in accordance with the NICE Guidelines, that he was not so told and therefore he was not given the information necessary to give informed consent. Therefore this is a return to the discredited paternalistic approach (c.f. Montgomery and Chester).
25. One aspect of the respondent's response to this is a submission that the principles to be derived from Montgomery and Chester are concerned only with harm – that is a failure to warn properly about risks of harm when that harm was then sustained. It is then argued that this case is different because there was no harm from the second arthroscopy. The respondent points out that the expert's joint statement recorded that they agree that no harm came to Mr Price as a result of that surgery.
26. Of course it is an important fact that the second operation did no lasting harm to Mr Price but I am not convinced this distinction justifies putting to one side the importance of personal autonomy and the need for patients to decide for themselves whether or not they would submit to a particular treatment. Although harm is the focus of much of the

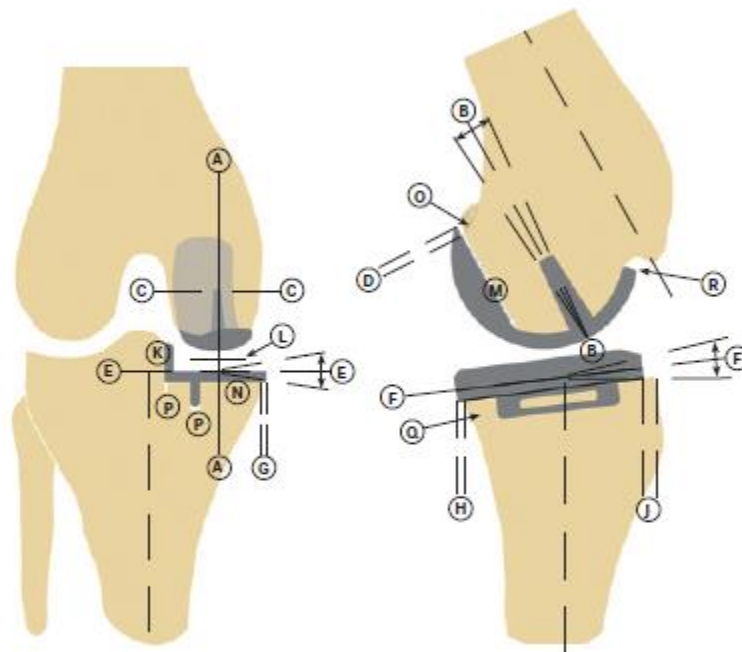
reasoning in the two authorities, I note the reference to dialogue and to anticipated benefits in paragraph 90 of the speech of Lord Kerr and Lord Reed in *Montgomery*.

27. The operation itself was an injury to Mr Price and if it was true (as is submitted on Mr Price's behalf) that this operation was pointless and had no benefits at all; and if it was also true (as is submitted) that Mr Price was not properly informed of that absence of benefit when asked to give his consent; then it seems to me those circumstances would vitiate the consent Mr Price had given.
28. However I have already rejected the argument that the operation was pointless. The judge found the operation had potential benefits for Mr Price and the appeal against that finding has failed. As to the consent process itself, I will start by addressing the main judgment without reference to the supplemental judgment. The first point is that the judge did not make an express finding that the potential benefits of the procedure were discussed with Mr Price at the point when he signed the consent form. However it is clear from the main judgment as a whole, including the reference in paragraph 66 itself to the clinic letter which does record a dialogue with Mr Price which included potential benefits, that the judge did not believe there was any flaw in the consent process itself. On the contrary his judgment was that the absence of a reference to potential benefits in the document was attributable to error rather than being evidence that the operation really was being performed for no reason at all. In other words reading the main judgment on its own, although he did not spell it out, the judge must have been satisfied that Mr Price had given his informed consent, which will have involved a discussion of the potential benefits. The evidence was sufficient to allow the judge to reach such a conclusion and therefore there is no reason to disturb that on appeal.
29. In fact I had arrived at the conclusion set out in the previous paragraph before I received the supplemental judgment. In his supplemental judgment the judge expressly states the same conclusion which I have found to be implicit in the main judgment. In the circumstances there is no need to address this any further.
30. That leaves the argument that in order for Mr Price to have given informed consent in these circumstances he had to have been additionally and expressly informed that the operation was not in accordance with the NICE Guidelines. There is certainly no suggestion that he was so informed and so if this is a good point the consent process was flawed. The only authority cited in support of the proposition was *R (Rose) v Thanet Clinical Commissioning Group* [2014] EWHC 1182 (Admin) in which the CCG was found to have been obliged to provide clear reasons for not following NICE Guidelines. However I do not accept that such a public law duty can or should be transposed by analogy into the process of obtaining a patient's informed consent. The appellant's skeleton argument also refers to *Bolitho v City & Hackney Health Authority* [1998] AC 232 but that case is not concerned with the question arising here about what needed to be put to Mr Price as part of the consent process.
31. In a clinical negligence case, the court's judgment about the content of the dialogue leading to a patient's consent will be fact sensitive. Whatever the position might be in other cases, I cannot see how the absence of a reference to these NICE Guidelines in these circumstances amounted to an infringement of Mr Price's personal autonomy or vitiated Mr Price's ability to make decisions for himself.

32. Standing back and considering the second operation as a whole, the judge clearly understood the evidence before him, came to conclusions open to him on the evidence and made no error in doing so. I reject this ground of appeal.

*Third operation*

33. On 19<sup>th</sup> January 2012, after the second arthroscopy, Mr Price again saw Mr Sharma. The letter to his GP records that Mr Price continued to have significant pain in his knee and was on restricted duties in a very demanding job which he wanted to carry on doing for as long as possible. A uni-compartmental knee replacement was discussed and Mr Price was added to the waiting list for that surgery. It was performed on Mr Price on 30<sup>th</sup> April 2012. The judge held that Mr Sharma was sufficiently experienced and trained to be able to carry out the procedure.
34. To explain the issue, it is necessary to focus on the prosthesis and its use. The judge did this in paragraphs 73-74 based on the manufacturer's manual. The prosthesis consists of three parts, a femoral component, a tibial component and a meniscal bearing. The femoral component is made of metal alloy and is fixed around the bottom end of the relevant condyle (bulge) on the end of the femur. The tibial component or tibial plate is also made of metal alloy and is fixed across the top of the relevant part of the tibia. The meniscal bearing is a moulded polymer material which fits in between the two metal components. The meniscal bearing fills the space between the two metal components. It has a flat bottom which rests on the flat upper surface of the tibial plate and a spherically concave upper surface into which the spherically convex lower surface of the femoral component engages. Being a polymer the meniscal bearing is not visible in X-ray images but it contains a thin radiopaque element which shows up as a thin line under X-rays.
35. A schematic diagram of the postoperative appearance is shown in the manual as follows:





36. The left hand diagram shows the anterior projection (i.e. the view from the front) and the right hand diagram shows the lateral projection. The dark parts are the metal components. The meniscal bearing is not shown. The manual specifies the acceptable limits of the position and size of the components. The relevant specification in this case relates to line A/A. The manual specifies that the acceptable limits for the femoral component relative to the femur for A/A are “<10° varus - <10° valgus”. In this context this means 10° side to side in the plane of the anterior projection diagram above. A/A is the line of the axis of the pin of the femoral component.
37. There is an issue about the reference axis against which that line is compared in order to make the angle. The judge referred to this ambiguity at paragraph 77. The reference axis is either the axis of the femur bone itself (called the anatomical axis) or else it’s the axis along which the weight is borne (called the mechanical axis). The anatomical axis runs along the shaft of the femur whereas the mechanical axis runs from the femoral head, which engages with the pelvis and is displaced to the side of the femoral shaft, down to the weight bearing point at the bottom of the femur. In an ideal situation the anatomical axis of the femur and the mechanical axis of the femur are at an angle of 7° to one another.
38. Another mechanical axis which was discussed in evidence is the mechanical axis of the whole limb. That runs from the femoral head to the ankle. The mechanical axis of the limb may not be co-incident with the mechanical axis of the femur, for example if a patient is knock-kneed (i.e. valgus) or bow-legged (i.e. varus). Mr Price’s legs are valgus.
39. The manual also includes x-ray images of the components ideally implanted. Figure 47 show the anterior projection:

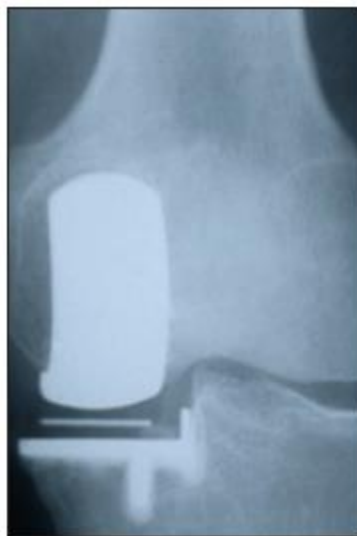

fig.47

40. The judge included the same figures I have set out (save for the lateral projection above) and also extracts from the text of the manual in paragraph 73 of the judgment. Part of that text from the manual relates to X-ray technique. As the judge recognised, this mandates a particular approach to taking X-ray images for the purposes of assessing alignment post operatively:

“Postoperative Radiographic Assessment

Good postoperative radiographs are necessary as a baseline for comparison with later films and to allow ‘quality control’ of the surgical technique.

For these purposes, the standard methods of aligning the X-ray beam are not sufficiently accurate, nor repeatable enough. To assess the positions of the two metal components, the X-ray beam must be centred on one component and aligned with it in two planes. The resulting projection of the other component can then be used to deduce their relative positions.

Radiographic Technique

Anterior Projection

In the anteroposterior projection, the patient lies supine on the X-ray table and the leg and the X-ray beam are manipulated under fluoroscopic control until the tibial component appears exactly end-on in silhouette, and the radiograph is then taken (fig. 47). In this projection, the alignment of the beam with the flat orthogonal surfaces (horizontal tray and vertical lateral wall and keel) allows great accuracy and reproducibility.

Lateral Projection

[...]”

41. The judge turned to the operation at paragraph 75. The issue he had to decide was about alleged misalignment of the femoral component. The judge recognised that the key evidence relevant to this was the radiology. The two radiology experts were Dr Euinton (called by Mr Price) and Dr Wilson (called by the respondents). He noted that on some issues Mr Rickman and Mr Weale deferred to the radiological evidence although they had their own views about what the images showed.
42. The two key X-ray images were an image taken on 1st May 2012 (i.e. the day after the operation on 30<sup>th</sup> April) and the Long Leg view which was the composite x-ray of three images taken on 15<sup>th</sup> October 2012 and stitched together digitally.
43. The 1<sup>st</sup> May 2012 image was taken with Mr Price lying supine. It shows the knee and some of the femur and tibia. The keel of the tibial plate appears as a line, which indicates it runs broadly into and out of the plane of the image. For the femoral component both the longer arc of the component and the shorter arc are visible, indicating that the component is turned slightly relative to the way it appears in figure 47 above.
44. The Long Leg view was taken when Mr Price was standing up. The pelvis and both legs are visible. Unlike the 1<sup>st</sup> May 2012 image, in the Long Leg image the hole in the keel of the tibial plate is visible. That does not mean the plate has moved. It indicates that the X-ray beam is at a different orientation relative to the tibial component from its

orientation in the 1<sup>st</sup> May image. The femoral component in the Long Leg image appears effectively as a rectangle, similar to figure 47 above and different from the 1<sup>st</sup> May 2012 image.

45. On a number of occasions during the hearing before me counsel for Mr Price drew attention to the fact that simply by looking at the Long Leg image, it appears that the axis of the femoral component is pointing in quite a different direction from the axis of the femur. In my judgment, beguiling though it is, that submission should be resisted. The interpretation of these X-rays is a matter for suitably qualified experts, or (which is really the same thing) for a judge once they have assumed the mantle of a suitably qualified expert with the assistance of appropriate expert evidence. Armed with that education the court may well be able to see and understand what the expert is talking about but that is quite a different matter from just looking at the pictures and reacting.
46. In the written evidence the radiology experts agreed that the “best images for alignment are the first post-operative images taken on 1<sup>st</sup> May 2012”. Nevertheless the experts also agreed that that radiograph is not entirely satisfactory because the beam is not well aligned with the components.
47. As the judge noted in paragraph 80, based on the Long Leg image Dr Euinton measured the angle between the mechanical axis of the right femur and the femoral component as 18°. The angle with the anatomical axis was 25°. The judge also noted that he agreed in cross-examination that the Long Leg view did not meet the Oxford radiographic criteria. As the judge also drew attention to, in re-examination Dr Euinton stated that the reason he had not said in the joint report that the best image for measuring alignment was the Long Leg view was because the image of 1<sup>st</sup> May 2012 was the best of the knee views whereas the Long Leg view was different and taken for a different reason. The point was that this evidence in re-examination was aimed at trying to explain an apparent inconsistency in Dr Euinton’s evidence between the agreed statement and his approach to the angle of misalignment based on the Long Leg view. The agreed statement was in answer to the question: “which if any radiographs meet the radiographic criteria for the assessment of alignment of an Oxford implant and why?”
48. Dr Wilson’s evidence recorded by the judge in paragraph 82 was that in the Long Leg view there was rotation of the knee on both projections such that it was not possible to make a reasonable assessment of the alignment of the implant. He did accept that to look at gross alignment of a component then a long leg image or an image with more bone at any rate was needed. Therefore, as the judge also noted in paragraph 82, Dr Wilson had also moved away from the simple position of the radiograph of 1<sup>st</sup> May 2012 being the best for measuring alignment. However the judge’s view was that Dr Wilson maintained that the images were very rotated and if there was malpositioning or rotation of lower limbs during the long leg images then there was no way reliably to accommodate this. It is said that in this respect the judge misunderstood Dr Wilson’s evidence. I will return to that below.
49. The judge’s conclusions on the third operation are in paragraph 83-87. Paragraphs 83 accurately summarised the issue. In paragraph 84 the judge held that he cannot draw any conclusions from the fact that after the operation Mr Price had persistent pain requiring revision surgery. The judge was entitled to do so because such symptoms were a recognised though rare non-negligent complication.

50. In paragraph 85 the judge noted that the respondent's case before him was that instead of reaching a finding that the angle was within or outside the 10° tolerance the court could simply conclude it was unable to reach a finding. He said that while it was tempting to say the case failed on the claimant's burden of proof, he believed that would be ducking the issue in reality.
51. The critical passages in the judgment are paragraph 86 and 87. In paragraph 86 the judge rejected the case on Mr Price's behalf that the court should be working from the Long Leg image. He gives three reasons for that conclusion stating that any one of which would be sufficient. The reasons are:

“Firstly, the long leg image does not comply with the Oxford Manual and I agree with the Defendant that when considering allegations of clinical negligence, the court should be concentrating on the requirements of the Manual rather than judging using imaging that does not comply.

Secondly, the majority of the literature that looked at angles of components did so using images of the knee and not long leg views, showing that the long leg view is not an accepted way of measuring an angle in such a situation.

Thirdly, the rotation of the leg in the long leg view in this case, as shown by the position of the patella and the visibility of the hole in the keel of the tibial component, means that the angle cannot be measured reliably.”

*[layout added]*

52. Then in paragraph 87 the judge found that the best image to work from is the 1<sup>st</sup> May 2012 image as originally agreed by the radiologists, albeit it is not an ideal image. He then undertook a brief process of reasoning noting the angle of the tibial component (6° per Dr Wilson, 3° to 4° per Mr Rickman), evidence from Mr Rickman whereby he agreed that the femoral component on the 1<sup>st</sup> May 2012 image appeared to be perpendicular to the tibial component albeit he did not agree this meant the femoral component was no more than 6° from the A/A line and concluding that he accepted the defendant's position that the way the femoral and tibial component are lined up in this 1<sup>st</sup> May 2012 image coupled with the fact that there is no challenge to the position of the tibial component, means that the angle of the femoral component does not exceed the 10° variance permitted by the Oxford manual. Therefore Mr Price's claim failed.
53. During the appeal a number of points taken fell away. There was a suggestion that the judge erred in paragraph 87 in the way he referred to the line A/A but that is not right and to the extent there is any ambiguity in the judgment about that, it is not material. The question whether the reference axis is the anatomical axis or the mechanical axis has no further significance as long as one keeps the difference between these two in mind.
54. On Mr Price's behalf both paragraph 86 and 87 are challenged. Nevertheless counsel for Mr Price accepted that if the challenge to paragraph 86 does not succeed, then the appeal must be dismissed because Mr Price's case would fail on the burden of proof

without the Long Leg view. There were other arguments aside from the Long Leg view, including submissions based on attempting to derive an angle consistent with Mr Price's case from the 1<sup>st</sup> May 2012 image, but on the evidence as a whole, without the Long Leg view the appellant cannot credibly establish his case that the angle is more than 10°. That is why counsel for Mr Price was right to accept as he did that the appeal fails if the argument on paragraph 86 fails.

55. The main points of the appellant's case on paragraph 86 are as follows:
- i) The first reason is wrong because the fact the image does not comply with the manual is not a good reason not to use it as evidence of what in fact the relevant angle is. The evidence of Dr Euinton and Dr Wilson as well as Mr Rickman was the long leg view was the best imaging view for assessing the position of the femoral component relative to the reference axis.
  - ii) The second reason is wrong because a significant portion of the literature used longer leg views and a significant number were silent as to which method was used. One paper (Gulati) referred to a weakness in this data because they did not have the benefit of long leg views.
  - iii) The third reason is wrong because the judge misunderstood the evidence on the effect of rotation. It was the evidence of Dr Euinton that taking into account rotation could only increase the angle from 17° and not reduce it. Dr Wilson and Mr Rickman agreed with this and Mr Weale did not demur.
  - iv) In any event, the judge wrongly misunderstood the limited relevance of the 1<sup>st</sup> May 2012 image which was not produced under fluoroscopic control either and did not allow for reliable measurements of the angle of the femoral component.
  - v) Further the judge failed to appreciate the relevance of the position of the keel of the tibial component when measuring gross alignment and failed to appreciate the significance of a second document from the manufacturer (Biomet) dated 2016 which supported the use of long leg views.
56. Starting with the first point, the judge was clearly right that the Long Leg view was not in accordance with the Oxford radiographic criteria. That is not the issue. The question is whether that fact alone is sufficient to justify setting aside that image. Counsel for Mr Price argued that this alone is not a sufficient reason for discounting the Long Leg view altogether. Effectively the argument is that the presence of the radiographic criteria in the manual does not mean an image which does not satisfy them contains no information relevant to the question of what the angle of the component actually is. In the abstract that may be so but the judge had evidence, for example from Mr Weale, to support his conclusion. Mr Weale said measuring the axis of the femoral component on that radiograph was "completely the wrong thing to do" and said "I don't think it's an appropriate radiograph to make measurements of varus or valgus alignment because it doesn't fulfil the strict criteria of the manual". However Mr Weale was not a radiologist. Turning to a radiologist, Dr Wilson also gave evidence that the reason the manual was very insistent on angles was because they got "nonsense pictures if we were slightly out of alignment". The point is not that the presence of radiographic criteria in the manual gives them a relevance, and if that is what the judge had meant then that would have been an error. However the point is that the radiographic criteria in the

manual are there for good reasons. That is what the judge was referring to. The judge had evidence on which to base his finding. The fact that there was other evidence going the other way does not mean his finding was not open to him. I reject this challenge to paragraph 86.

57. The second reason relates to the literature. I was taken through the papers themselves and the cross-examination on them. It is quite true that there are papers which use views which show more bone than the 1<sup>st</sup> May 2012 view (“longer” leg views), that some papers are silent on the matter and that one paper which studies the alignment of the relevant components does mention as a limitation in its study the lack of full length radiographs for measuring alignment (Gulati (2009)). However having been through all this evidence, in my judgment it is plain that the judge’s summary of the import of the scientific literature in paragraph 86 was a conclusion which was open to him on the evidence. I am not certain the first and second reasons are really independent of each other nor do I think either could stand alone if the other was falsified but that is not what happened.
58. The third reason relates to the rotation in the Long Leg image itself. The problems with the image are apparent. The debate is whether the judge misunderstood the evidence about the impact of these problems. On Mr Price’s behalf it is submitted that rotation could only ever increase the misalignment angle and so whatever angle was measured in the Long Leg view (at least 18°), that represented a minimum and therefore proves that the femoral component was aligned at more than 10° to the axis. This was Dr Euinton’s evidence at trial, which he sought to demonstrate using straws. In that respect he had moved away from the position in the joint report that he had agreed there was no way to reliably accommodate malpositioning or rotation of the limbs in the long leg images. It is submitted that Dr Wilson accepted this in cross-examination. In other words the case for Mr Price is that the radiologists were in agreement about the minimum angle point.
59. It is fair to say that Mr Weale did maintain that the rotation in the Long Leg view meant the alignment of the femoral component could not be assessed but he was not the radiologist and as the judge recognised, the radiology was the key.
60. The judgment does not refer to the minimum angle argument and the reference to the joint report in the last sentence of paragraph 82 does not grapple with the fact that Dr Euinton had given different evidence at trial (i.e. the minimum angle point). Reading the judgment it is not obvious what the judge thought about this argument.
61. At trial the point about the minimum angle and Dr Wilson’s acceptance of it was put at the forefront of the closing submissions for Mr Price regarding the third operation. The contrary submission for the respondents was that the evidence in Dr Wilson’s cross-examination (which does start with the word “yes” after the question about the minimum angle) had to be seen in the context of what Dr Wilson went on to say afterwards. What Dr Wilson went on to say was that the Long Leg view was used for getting the overall alignment of the leg and not for assessing the implant. He said the “AP close up view” (which is what the 1<sup>st</sup> May 2012 image is but the Long Leg view is not) is used to see the varus/valgus position of the femoral component.
62. Seeing how the matter was put to the judge at trial allows one to understand his approach in the judgment. The judge has essentially followed the way the respondent

put the case on this point. The judge placed the emphasis on the part of Dr Wilson's evidence which came down to an opinion that the Long Leg view was not useful for assessing the implant because of the problem of rotation. That is how the judge characterised Dr Wilson's evidence in paragraph 82 of the judgment (before the last sentence about the joint report). It was something Dr Wilson went on to maintain despite the evidence about a minimum angle. Therefore the judge did not misunderstand Dr Wilson's evidence. Having heard all the witnesses, it was open to the judge to reject reliance on the Long Leg view in this way and, as part and parcel of that, to not place weight on the minimum angle point.

63. In the light of the prominence given to the minimum angle point in the case advanced on Mr Price's behalf, the judgment ought to have mentioned it. If it had, then the error in the last sentence of paragraph 82 about Dr Euinton's evidence would not have been made. However as I have explained, I am not satisfied that that error or the point itself demonstrates the judge reached a conclusion which was not open to him on the evidence.
64. Before leaving paragraph 86 I will address the other two issues. First the argument about the limited relevance of the 1<sup>st</sup> May 2012 image. This is really a point against paragraph 87. Nevertheless it is not a good point. It was open to the judge to decide that the 1<sup>st</sup> May 2012 was the best image to work from and he did so fully aware that it was not an ideal image. The fact it had not been produced under fluoroscopic control was one reason why it was not ideal.
65. As for the 2016 document from the manufacturer (Biomet), there is text in that document which refers to long leg images but a reasonable interpretation of that text is that the long leg X-rays referred to are needed for precise measurement of alignment of the limb. That supports the respondent's case and does not advance the appeal.
66. As explained already, upholding paragraph 86 is sufficient to dispose of this appeal and it is not necessary to consider paragraph 87. I will say only that I was not convinced that the challenge to paragraph 87 would succeed. There was cross-examination on the point that the femoral component did indeed appear to be perpendicular to the tibial component and although Mr Rickman did not accept that that meant the femoral component was not misaligned, the judge's finding seems to me to have been open to him on the evidence as a whole. However most importantly of all, the best the argument about paragraph 87 could be for Mr Price is that one cannot say that the angle is less than 10°. That is not enough to succeed on appeal without the Long Leg view.
67. Standing back looking at the whole section on the third operation, I am not satisfied there is any ground for overturning the judge's conclusions.

### *Conclusion*

68. Like the judge, I have great sympathy for Mr Price and what has happened to him. Nevertheless I dismiss the appeal.